

ACKNOWLEDGMENTS

The author would like to thank Capt. Benjamin Kolle, Chief of Optometry, 47th Medical Group, Laughlin AFB, TX, for his review of this article. The views expressed in this article are those of the author and do not necessarily reflect the official policy or position of the Air Force, the Department of Defense, or the U.S. Government.

REFERENCES

1. Federal Aviation Administration. Press release – FAA to impose civil penalties for pointing lasers into cockpits. 2011. [Accessed 1 Sept. 2015]. Available from https://www.faa.gov/news/press_releases/news_story.cfm?newsId=12765.
2. Federal Aviation Administration, Civil Aerospace Medical Institute. Laser hazards in navigable airspace. Oklahoma City (OK): Civil Aerospace Medical Institute; (n.d.). [Accessed 1 Feb. 2016]. Available from http://www.faa.gov/pilots/safety/pilotsafetybrochures/media/laser_hazards_web.pdf.
3. Glickman RD. Phototoxicity to the retina: mechanisms of damage. *Int J Toxicol*. 2002; 21(6):473–490.
4. Kasaoka M, Ma J, Lashkari K. c-Met modulates RPE migratory response to laser-induced retinal injury. *PLoS One*. 2012; 7(7):e40771.
5. Lim ME, Suelzer J, Moorthy RS, Vemuri G. Thermal macular injury from a 154 mW green laser pointer. *J AAPOS*. 2014; 18(6):612–614.
6. Naval Aerospace Medical Institute. U.S. Navy aeromedical reference and waiver guide. Pensacola (FL): Naval Aerospace Medical Institute; 2016. [Accessed 1 Feb. 2016]. Available from <http://www.med.navy.mil/sites/nmotc/nami/arwg/Pages/default.aspx>.
7. Office of the Chief of Naval Operations. Naval aviation safety management system. Washington (DC): Department of the Navy; 2014. Report No.: OPNAVINST 3750.6S.
8. Office of the Law Revision Counsel of the U.S. House of Representatives. Aiming a laser pointer at an aircraft. 18 U.S.C, § 39A (2012).
9. Shenoy R, Bialasiewicz AA, Bandara A, Isaac R. Retinal damage from laser pointer misuse – case series from the military sector in Oman. *Middle East Afr J Ophthalmol*. 2015; 22(3):399–403.
10. Stanford University. Stanford University laser safety manual. 2012. [Accessed 1 Sept. 2015]. Available from <http://web.stanford.edu/dept/EHS/prod/researchlab/radlaser/laser/program/>.
11. U.S. Army. Standards of medical fitness. Washington (DC): Department of the Army; 2011. Army Regulation 40-501. [Accessed 1 Feb. 2016]. Available from http://armypubs.army.mil/epubs/pdf/r40_501.pdf.
12. U.S. Army Public Health Command. LASER exposure incident reporting. Aberdeen Proving Ground (MD): U.S. Army Public Health Command; (n.d.). Fact Sheet 24-028-0615. [Accessed 1 Feb. 2016]. Available from https://phc.amedd.army.mil/PHC%20Resource%20Library/LASERExposureReporting_FS_24-028-0615.pdf.
13. Wyruch S, Baenninger PB, Schmid MK. Retinal injuries from a handheld laser pointer. *N Engl J Med*. 2010; 363(11):1089–1091.

This article was prepared by Michelle R. Milner, M.D., M.P.H.

You are in the middle of a busy clinic day when you get an instant message from one of your helicopter pilots asking if you have time to see him. You take a quick look at the notes from his previous visits and notice he's seen a few other docs in the clinic for recurrent pharyngitis while you were on temporary duty the past few weeks.

1. Which of the following is a reason to maintain primary care manager continuity of care^{1,7} for this patient?

- A. Decreased emergency department visits.
- B. Increased efficiency.
- C. Improved screening and behavior modifications.
- D. ALL of the above are excellent reasons to maintain continuity of care.

ANSWER/DISCUSSION

1. D. You always want to see your patients, and one of the best parts of being a flight doc is that your patients prefer to see you as well. You've learned through research and experience that a single primary care doc improves patient-physician communication, increases trust, and decreases emergency room visits. You also know that if you truly know your patients, you will be able to advocate for them when needed and you will be first to notice subtle changes.

Of course, you ask him to come to the clinic at his convenience. You review his notes more thoroughly to remind yourself he is a 26-yr-old healthy helicopter pilot. He appears to have had a sore throat for several weeks and was seen by two colleagues who ordered lab work. He uses “dip” and alcohol once or twice weekly.

2. What is your very generic differential diagnosis in an otherwise healthy 26-yr-old male pilot presenting with sore throat, intermittent fever, no cough, and no diarrhea?

- A. Viral pharyngitis.
- B. Infectious mononucleosis.
- C. Gonococcal pharyngitis.
- D. Streptococcal pharyngitis.
- E. ALL should be on your early differential diagnosis.

ANSWER/DISCUSSION

2. E. Viral pharyngitis typically presents with a headache, coryza, conjunctivitis, and fatigue and is the most common diagnosis for this cluster of symptoms. While this potentially sounds like our patient,

DOI: <https://doi.org/10.3357/AMHP:4767.2017>

other symptoms may point you toward different etiologies. This patient's age could point to infectious mononucleosis, so an exam for exudates on the tonsillar pillars and posterior lymphadenopathy will be important. The military patient population is typically considered sexually active, which adds gonococcal pharyngitis to our list, prompting us to get a sexual exposure history and to look for a greenish exudate.² While these are all possible, streptococcal pharyngitis is also high on the list. If positive, treatment to prevent peritonsillar abscess and rheumatic fever, while rare, should be considered. Luckily, we have criteria to review to help determine if a rapid strep test should be run.

3. A review of the Armed Forces Health Longitudinal Technology Application (the military's electronic health record) shows which labs have been ordered?

- A. Rapid antigen or rapid strep antigen test.
- B. Throat culture.
- C. Monospot test.
- D. Any of the above would be appropriate, depending on index of suspicion.

ANSWER/DISCUSSION

3. D. The group A streptococcal (GAS) rapid antigen test was positive for this patient multiple times. A GAS throat culture was positive with sensitivity to penicillin, amoxicillin, erythromycin, and cephalixin. The throat culture was negative for gonococcus and the Epstein-Barr serum monospot was also negative.

The Air Force family health clinics saw over 54,000 cases of pharyngitis in 2015; Air Force flight medicine clinics saw less than 9000 cases in the same year (Park J. CAPE-RS analysis; unpublished raw data; 2015 Oct. 26). While this is a common diagnosis, flight medicine staff have fewer opportunities to treat it, so reviewing the Centor criteria—an indication for GAS testing and treatment—can be helpful to avoid unnecessary testing, potentially providing a confusing picture. The Centor criteria have been around for many years and were recently revalidated by the American College of Physicians and supported by the Centers for Disease Control and Prevention in 2012. They are:

- Pus on tonsils (+)
- Adenopathy (+)
- Fever (+)
- Cough (–)

The above Centor criteria score one point for each symptom agreement. A score of 0 indicates no treatment or testing is required. A cumulative score of 1, 2, or 3 suggests a throat culture or GAS rapid antigen test, while a score of 4 does not require testing and can be treated empirically. The modified Centor score adds age criteria, with 3-14 yr receiving 1 point while 15-44 yr receives 0 points; the rarity of GAS pharyngitis in an older population dictates a subtraction of 1 point for patients older than 45 yr.² Our 26-yr-old patient had a fever and no cough, giving a score of 2. Therefore, testing was indicated and appropriate.

With a positive GAS test and persistent symptoms, he was treated with the typical first-line antibiotic,⁴ penicillin, 500 mg twice daily. This helped almost immediately, but his symptoms returned about a week after completing a 10-d course. Upon his next visit, he was treated with a Z-pak with moderate benefit, noting less improvement than with the penicillin. Unfortunately, his symptoms returned almost immediately upon completion of this 5-d course.

An exam of this helicopter pilot shows a moderately ill appearing young man with stable vital signs other than a mildly elevated temperature of 100°F. You are a little startled to find a mass on his right anterior neck, approximately 6 cm by 4 cm. When you gently palpate this mass, it is tender and fluctuant. A bit more concerning is his comment that this palpation gives him a “full feeling” in his throat. His oropharynx, while mildly erythematous, shows no evidence of this mass and no evidence of purulent material.

4. What is your top diagnosis?

- A. Activated lymph node in the anterior cervical chain.
- B. Papillary thyroid cancer.
- C. Infected branchial cleft cyst.
- D. Esophageal cancer.

ANSWER/DISCUSSION

4. C. This is too large to safely be dismissed as an activated lymph node; more evaluation would make this clearly not lymphoid tissue. While thyroid cancer can certainly cause a mass this large, the mass would be more midline than this is presenting. Esophageal cancer could be on your differential, especially given his tobacco history, although dysphagia would be expected and he does not report this. While an unusual diagnosis, an infected branchial cleft cyst must be in the back of your mind.

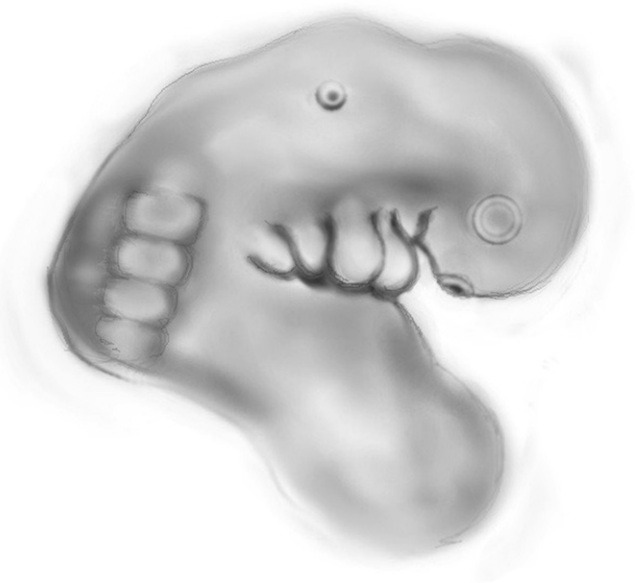


Fig. 1. Embryo showing nasal and lens placodes cephalad and pharyngeal arches caudad with somites surrounding the neural tube on the dorsum. (Illustration by Alecia C. Milner.)

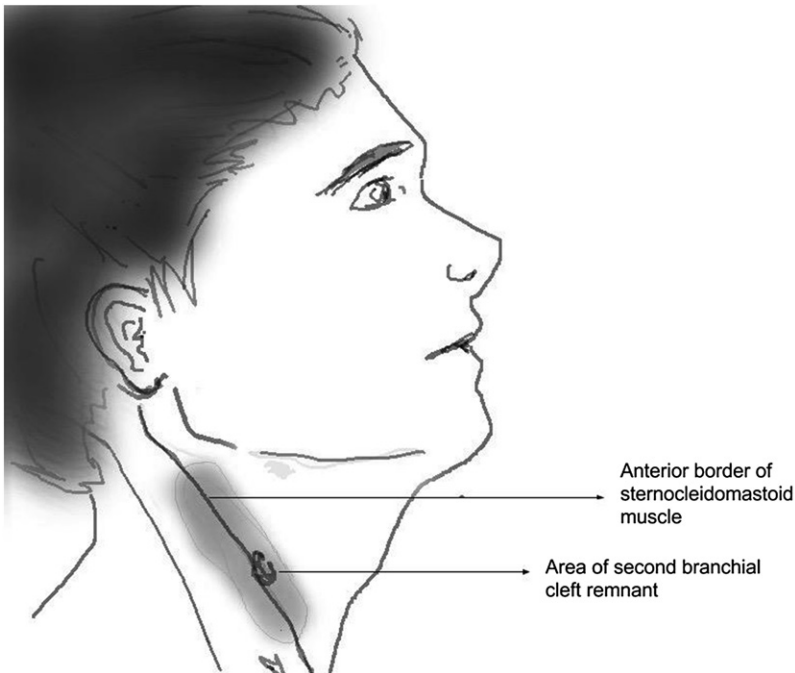


Fig. 2. Second branchial cleft remnant anterior to the border of the sternocleidomastoid muscle. (Illustration by Alecia C. Milner.)

5. Based on the location of the mass, which branchial cleft is most suspect?

- A. First.
- B. Second.
- C. Third.

ANSWER/DISCUSSION

5. B. A brief refresher regarding embryonic tissue at this point: clefts give rise to ectoderm, pouches generate the endoderm, while arches produce the mesoderm (Fig. 1). These structures are the embryonic precursors to the head and neck structures. As the name indicates, clefts lie between the arches and a cyst is an unobliterated cleft remnant. The second branchial cleft is the most common remnant to become infected. Since this embryonic formation ultimately creates parts of the tonsillar pillars, it is no surprise to find the infected cystic remnants in this region (Fig. 2). Of important note, while this finding is not uncommon in 20- to 30-yr-olds, cancer should be suspected in anyone with a branchial cleft cyst over the age of 40 until proven otherwise.⁵

While this presentation can leave a provider relatively confident in the diagnosis, ultimately an ultrasound or computed tomography scan should be obtained. Findings will include a homogenous cyst with a highlighting rim. While rare, if a third cleft cyst is suspected, based on purulent material draining via a fistula, fluoroscope or computed tomography fistulography should be considered. A cyst in the third or fourth cleft region would support a barium swallow to assist with fistulae localization.⁸ Due to the high risk of cancer in any patient over the age of 40 yr, a fine needle aspiration to rule out cancer is advised. If the patient is very ill or has a concurrent cellulitis, antibiotics for 2 wk prior to surgery may be desired by the surgeon.

As surgery is the definitive treatment, risks should be reviewed with the pilot. Of course, because of the local structures, there is risk to musculature, the brachial plexus, and the common carotid artery. There is also a risk of recurrence if the entire cyst wall is not removed. Recovery is relatively benign, with the incision typically healing well in a matter of weeks.

AEROMEDICAL DISPOSITION

While this diagnosis does not limit duties in the Air Force, Army, or Navy, nor does it limit certification through the Federal Aviation Administration,^{3,6,9,10} the surgical correction does merit discussion. Postoperatively, once released from care by the surgeon, an aviator must be able to perform all duties as he or she did prior to the illness and surgery. This includes, but is not limited to, a return of full range of motion for the head and neck as well as clear speech. Documentation of a well-healed surgical scar is required for the Federal Aviation Administration³ and makes for a complete picture in the Services. This helicopter pilot

healed very nicely and was able to return to full duty after only 4 wk of convalescent leave.

Milner MR. *You're the flight surgeon: an unusual case of pharyngitis.* *Aerosp Med Hum Perform.* 2017; 88(4):439–442.

ACKNOWLEDGMENTS

The author would like to thank Colonel (Dr.) Lakeisha Henry, Commander, 779th Surgical Operations Squadron, Air Force Surgeon General Otolaryngology Consultant, for her guidance and assistance, as well as Alecia C. Milner for the included artwork. The views expressed in this article are those of the author and do not necessarily reflect the official policy or position of the Air Force, the Department of Defense, or the U.S. Government.

REFERENCES

1. Alazri M, Heywood P, Neal RD, Leese B. Continuity of care: literature review and implications. *Sultan Qaboos Univ Med J.* 2007; 7(3): 197–206.
2. Choby BA. Diagnosis and treatment of streptococcal pharyngitis. *Am Fam Physician.* 2009; 79(5):383–390. Erratum in *Am Fam Physician.* 2013; 88(4):222.
3. Federal Aviation Administration. Guide for aviation medical examiners. Washington (DC): Federal Aviation Administration; 2016. [Accessed 30 June 2016]. Available from http://www.faa.gov/about/office_org/headquarters_offices/avs/offices/aam/ame/guide/media/guide.pdf.
4. Fine AM, Nizet V, Mandl KD. Large-scale validation of the Centor and McIsaac scores to predict group A streptococcal pharyngitis. *Arch Intern Med.* 2012; 172(11):847–852.
5. Moss-Salentijn L. Pharyngeal arches and pouches. (n.d.). [Accessed 18 Sept. 2015]. Available from <http://www.columbia.edu/itc/hs/medical/humandev/2006/HD13/HD13.pdf>.

6. Naval Aerospace Medical Institute. U.S. Navy aeromedical reference and waiver guide. Pensacola (FL): Naval Aerospace Medical Institute; 2016. [Accessed 30 June 2016]. Available from <http://www.med.navy.mil/sites/nmotc/nami/arwg/Pages/AeromedicalReferenceandWaiverGuide.aspx>.
7. Rosser W, Schultz K. Promoting continuity of care should be integral to any health care system. *CMAJ*. 2007; 177(11):1385–1386.
8. Triglia JM, Nicollas R, Ducroz V, Koltai PJ, Garabedian EN. First branchial cleft anomalies: a study of 39 cases and a review of the literature. *Arch Otolaryngol Head Neck Surg*. 1998; 124(3):291–295.
9. U.S. Air Force. Medical examinations and standards. Washington (DC): Department of the Air Force; 2013. Air Force Instruction 48–123. [Accessed 30 June 2016]. Available from http://static.e-publishing.af.mil/production/1/af_sg/publication/afi48-123/afi48-123.pdf.
10. U.S. Army. Standards of medical fitness. Washington (DC): Department of the Army; 2011. Army Regulation 40–501. [Accessed 30 June 2016]. Available from <http://www.apd.army.mil/Search/ePubsSearch/ePubsSearchDownloadPage.aspx?docID=0902c85180010d99>.