

Aortic Root Aneurism Found in a 42-Year-Old Epitomizes the Importance of Auscultation in Routine Exams

Todd R. Fredricks; Jeffrey S. Benseler

- BACKGROUND:** Bicuspid aortic valve disease (BAV) is the most common cardiac valve pathology. BAV is associated with aortic root disorders. The literature has few case reports identifying this condition during routine physical exam.
- CASE REPORT:** A 42-yr-old military reservist flight medic presented for his annual military flight physical. He was found to have a faint cardiac murmur. His past family and medical history were remarkable for familial essential hypertension and being told at age 9 that he had a “murmur.” He was referred for cardiology consultation, echocardiography, stress testing, and a computerized tomography angiogram (CTa), which identified BAV with a 4.3-cm aortic root aneurysm. A follow-up at 1 yr was recommended. In the interim he developed severe aortic valve insufficiency, a 4.6-cm aortic root aneurysm. The valve and aortic root were repaired and a single left anterior descending coronary artery lesion was bypassed during surgery. The flight medic made a full recovery but was not returned to flight status.
- DISCUSSION:** This case emphasizes the importance of periodic reassessment by thorough history and careful cardiac auscultation during flight physicals. BAV aortopathy is an uncommon condition seen in the military aviation community. Most flight surgeons will not have the opportunity to identify it specifically via auscultation. This patient had over nine annual flight physicals prior to the one reported and no pathology was ever identified through routine auscultation. The potential role of point-of-care ultrasound (POCUS) for survey of vascular and valve status of aviation personnel merits further research.
- KEYWORDS:** auscultation, aortic root aneurysm, bicuspid aortic valve, murmur, flight.

Fredricks TR, Benseler JS. Aortic root aneurism found in a 42-year-old epitomizes the importance of auscultation in routine exams. *Aerosp Med Hum Perform*. 2016; 87(5):487–492.

Systolic murmurs are the most common abnormal cardiac auscultatory finding in both children and adults.² Bicuspid aortic valve disease (BAV) is the most common congenital heart defect presenting with murmur. A bicuspid aortic valve has two leaflets in contrast to the normal aortic valve's three leaflets (Fig. 1).

The leaflets can vary in structure, degree of symmetry, and functionality between individuals with BAV. BAV has a prevalence between 0.5 and 2% in the general population. The disease affects males between 2 and 3 times more often than females.^{6,16} Although BAV is strongly genetically linked, a uniform description of a specific model of inheritance is not easily described. Comparisons of different family groups have shown that the disease is inherited with dissimilar patterns and via mutations in diverse genes.⁶ BAV is also associated with ascending aortic root aneurysm known as BAV-aortopathy. This link

between BAV and aortopathy was first described by Abbot in 1928.¹ Since then further investigation has shown that both hemodynamic effects such as abnormal flow turbulence and cellular level structural changes are also present in the aortas of patients presenting with BAV-aortopathy.^{9,13} Hemodynamic flow changes can occur even in functionally “normal” BAV. Patients with hemodynamically “normal” BAV have larger aortic diameters on average than patients with tricuspid aortic valves.

From the Ohio University Heritage College of Osteopathic Medicine (OUHCOM), Athens, OH.

This manuscript was received for review in July 2015. It was accepted for publication in February 2016.

Address correspondence to: Todd R. Fredricks, D.O., Department of Family Medicine, OUHCOM, Athens, OH 45701; fredrick@ohio.edu.

Reprint & Copyright © by the Aerospace Medical Association, Alexandria, VA.

DOI: 10.3357/AMHP.4431.2016

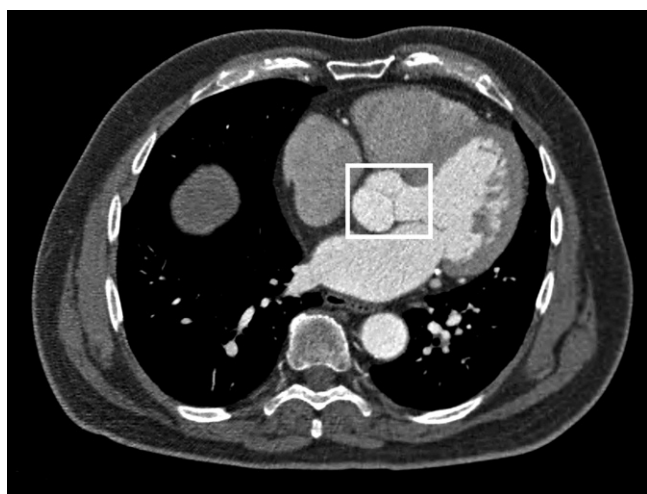


Fig. 1. CTa demonstrating the nominal tricuspid architecture of the aortic valve, which resembles an inverted “Y” shape or “Mercedes sign” (white box).

It bears repeating that aneurysm formation and dissection of the ascending aorta can result in particularly catastrophic consequences.⁸

A diameter of 5.5 cm or larger and/or growth of >0.5 cm diameter per year is the current indication for repair of uncomplicated aortic aneurysm. When accompanied by indications for elective aortic valve replacement or repair, the aneurysm repair is indicated at 4.5 cm.⁹ Due to current trends in the management of BAV, aortic dissection is a rare occurrence; however, the implications of this complication during flight operations are not trivial.

CASE REPORT

A 42-yr-old Caucasian male flight paramedic presented for his annual military flight physical in August 2012. His family medical history was positive only for essential hypertension. The patient was normotensive. His social history was positive for smokeless tobacco (3 cans per week) and negative illicit drug use. He engaged in moderate (3-5 drinks, 2 times a week) alcohol consumption. He regularly walked or ran 3-4 times per week to train for his U.S. Army physical fitness test. His medical history was positive only for mild dyslipidemia: total cholesterol 215, HDL 44, LDL 147, triglycerides 121. His annual 12-lead EKG showed normal sinus rhythm and was otherwise unremarkable. During the exam the flight surgeon detected a subtle systolic ejection murmur, graded 1/6, best heard over the cardiac apex and with less intensity at the parasternal listening posts. Dynamic auscultation via Valsalva and positioning did not change the murmur. When asked if he had ever had a murmur the patient replied that he had been told that he had one at age 9, but was unaware of any murmur in adulthood. He had not undergone further assessment for the pediatric murmur. The examining reservist flight surgeon was very familiar with the patient. The flight surgeon had not detected any cardiac murmurs on any of the patient's nine previous annual exams.

Because the murmur was new the patient was referred for cardiology consultation and echocardiography. He had transesophageal echocardiography within a month of his initial presentation and he was found to have a bicuspid aortic valve with a ~4.3-cm aortic root aneurysm. No aortic stenosis was noted. Ejection fraction was measured at 60%. There was moderate aortic insufficiency. The ventricles were determined to have normal motion, size, and thickness. All other valves were deemed to have normal architecture and function. After review of the ultrasound study the patient was advised by the consulting cardiologist to follow up in 1 yr for repeat echo and resume all normal activities. To comply with U.S. Army waiver standards, a Bruce protocol exercise stress test (GXT) was conducted to 11.4 METs with a maximum predicted heart rate of 95%. No chest pain or acute changes were noted and it was deemed normal. A 24-h Holter monitor showed a normal sinus rhythm, 43 PVCs, and a mean heart rate of 70 with minimum and maximum rates of 46 and 112 bpm, respectively. Due to operational concerns a return to flight status during this period was not attempted.

The patient underwent a repeat echocardiogram 1 yr later. At this time he reported episodes of mild shortness of breath, but his physical status was otherwise unchanged. His echocardiogram demonstrated persistent aortic valve insufficiency with an ejection fraction of 58.89%. The cardiologist requested a computerized tomography angiogram (CTa) to evaluate the aortic root aneurysm. The root maximum diameter was ~4.6 cm (4.44 cm at the calipers) with a nondissecting aneurysm (Fig. 2).

The descending aorta diameter opposite the root was 2.8 cm. Coronary calcifications were noted. Cardiac catheterization was ordered. The left anterior descending artery was found to have a 40–50% narrowing with a distal ulcerated plaque. This study showed severe aortic insufficiency with mild left ventricular dysfunction and an estimated ejection fraction of 40–45%. Surgery was scheduled based upon the rate and degree of both valvular decompensation and aneurysmal growth. The patient received an ON-X® mechanical valve with successful repair of his aneurysm in February 2014. He was placed on simvastatin 10 mg daily, metoprolol 50 mg twice daily, and Coumadin 5 mg daily.

During his 2-mo postoperative cardiac rehab period he went to his local emergency room with shortness of breath. Imaging revealed only changes consistent with postoperative status (Fig. 3). He had a repeat CTa and no defects were identified.

His dyspnea was determined to be due to a combination of deconditioning and postoperative effects. His post-cardiac rehab GXT achieved 13.5 METs without significant dyspnea. He was released for full duties in June of 2014. He remained physically active 7 mo post-surgery. His lipid profile included a total cholesterol of 171, HDL of 45, LDL of 110, and triglycerides of 163. The patient was not returned to flight status due to anticoagulation and his expressed loss of interest in continuing aviation duties.

DISCUSSION

Even with careful screening for defects prior to being selected for flight status the effects of aging and limitations of general medical

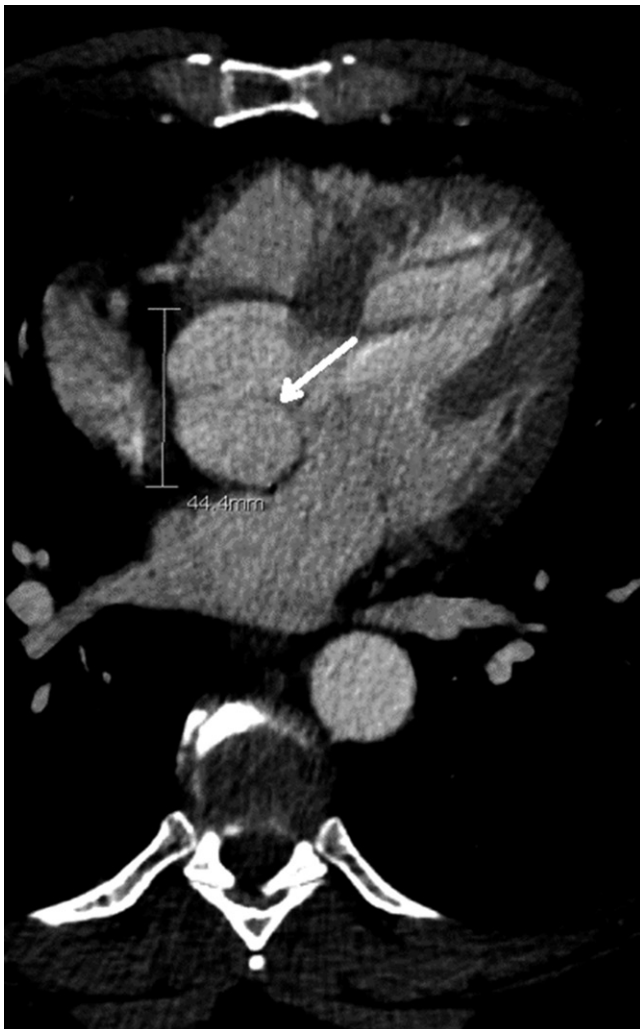

Fig. 2. CTa demonstrating the “line sign” of the patient’s preoperative bicuspid valve (white arrow) and aortic root aneurysm at 4.4 cm (calipers).

exams can miss underlying pathologies that can lead to poor outcomes. In spite of civilian and military aviation medical reporting requirements, initial flight applicants may not report medical conditions of childhood that have not caused them any troubles. Reasons for this can be simple oversight or in some cases secondary gain (e.g., attaining flight status). This patient’s training as a critical care paramedic and lack of symptoms suggested to him that the murmur he had at age 9 was inconsequential. He simply did not think to report it when he entered the military.

The dissection of an aortic root aneurysm during flight would have been catastrophic for the patient. If it had occurred while transporting a critical patient that individual could have suffered harm. Concerns of in-flight incapacitation and possibly being unable to care for a critically ill patient led to this patient’s loss of interest in continuing to work as a flight medic. He decided that he felt more comfortable working as a ground critical care transport paramedic since he would always be working with another skilled medical provider.

For the flight surgeon this case emphasizes the importance of both periodic history review and careful auscultation. The

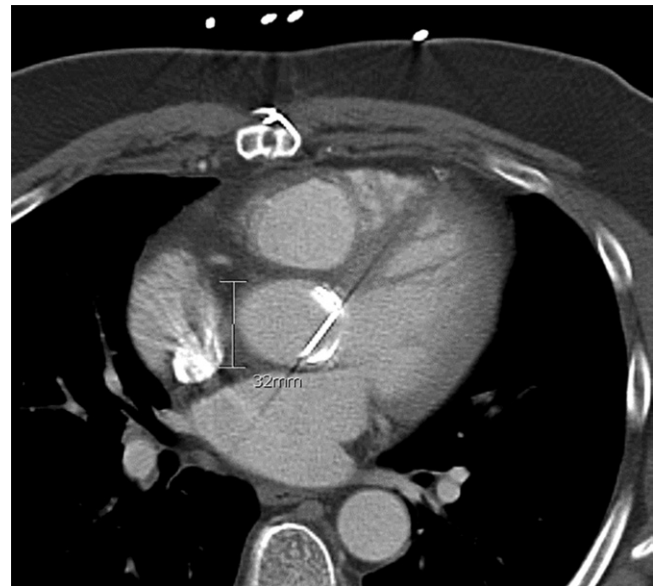


Fig. 3. CTa demonstrating postoperative changes and a repaired root diameter of 3.2 cm (calipers).

patient’s murmur was almost imperceptible by stethoscope. It was detected during a nominal exam in which dynamic auscultation of all four traditional cardiac listening posts was conducted.⁵ This exam takes 90 to 120 s provided no pathology is identified. In this case the flight surgeon had known and annually examined the patient for nearly a decade. This relationship was instrumental in the flight surgeon detecting the murmur. No murmur or historical account that suggested murmur had ever been identified during previous history taking and examination.

Although the value of competent cardiac auscultation in identifying significant valvular heart disease is clear,¹² numerous studies over the past two decades have identified deficiencies in the auscultatory abilities of physicians. These deficiencies are most apparent in practicing family medicine and general internal medicine physicians, the specialties most likely to be conducting both military and civilian aviation medical screening exams.¹⁰ While it could be inferred that increases in clinical workloads resulting in less time available with each patient could be contributing to the loss of auscultatory proficiency, it has also been suggested that it may be due to an overreliance on technologies such as ultrasound to establish diagnosis and a failure to regularly and carefully auscultate patients during exams.^{5,17} Reliance on technology is problematic because unless the examining physician detects a murmur or abnormality through practical auscultation, it is unlikely that they will order a cardiac ultrasound. Further, the practice of referring patients to cardiologists to obtain formal echocardiographic ultrasound for the routine evaluation of an asymptomatic, “innocent” systolic murmur found during an otherwise unremarkable history and clinical exam is both costly and seldom if ever indicated.² Thus technology cannot and should not replace physician proficiency in auscultation as the front line tool for early identification of cardiac and vascular disease.

Research designed to improve deficits in cardiac auscultation has shown that repetition in practice via listening to

recordings of cardiac murmurs, as well as live patients, is of substantial benefit in diagnosis of valve disease.^{3,11,14} In this case the murmur heard did not reflect the classically defined murmur of the pathology found. In cases of BAV a systolic murmur is usually found when aortic stenosis is present. This was not found in this patient. The moderate aortic regurgitation found during the patient's echo should have revealed itself as a diastolic murmur at the apex and this was not appreciated on the patient's exam. A grade II decrescendo diastolic murmur would account for the patient's murmur, but even after careful listening while palpating the patient's radial pulse, the flight surgeon felt that he heard the murmur in systole.

While repetitive listening to example murmurs improves auscultatory accuracy, in busy general practices finding the time to do this would not be simple for most flight surgeons. The patient's flight surgeon works as a medical school professor teaching exam skills to first year medical students. He attributed his recognition of the murmur to continuous exposure to and demonstration of cardiac exam to students in his clinic and skills lab. However, most of these patients and patient models have no cardiac pathology and thus the opportunity to hear actual cardiac murmurs in practice is limited. In aviation, and particularly military aviation, the screening processes leading to pilot selection further limits the presence of cardiac pathology. Because of this a more feasible methodology for practicing flight surgeons to discriminate innocent from potentially malignant murmurs might be to emphasize the importance of learning and knowing "normal." The repetitive value of auscultating cardiac sounds during every patient encounter, regardless of presenting complaint, to condition the examiner's ear to "normal" cannot be overemphasized.

The focus on normal should not be misunderstood as a license to forgo a deeper knowledge of the presentation of abnormal cardiac auscultatory findings. Nor should it be construed to mean that any murmur heard is suspect and should be referred for cardiology evaluation. In fact, the skilled flight surgeon should be able to recognize benign sounds sometimes associated with cardiac auscultation such as Still's murmurs, mammary soufflé, and low grade (I or II) midsystolic murmurs. When coupled with unremarkable history in an asymptomatic patient these sounds are innocent and do not require further work-up.⁴ Understanding and recognizing them can save both the patient and cardiologist from an unnecessary referral.

As a rule diastolic murmurs, systolic murmurs of grade III or higher, murmurs that improve with squatting (i.e., hypertrophic obstructive cardiomyopathy), and any new or worsening murmur associated with constitutional complaints such as shortness of breath or chest pain is serious and should be referred for echocardiographic evaluation. Though they risk oversimplification, flow charts with these general guidelines have been created and can serve to simplify the evaluation and referral process for flight surgeons.⁴

This case also illustrates how nonauscultatory screening criteria can potentially lead a flight surgeon to a false sense of security regarding aviation personnel cardiac health. The patient's only risk factors for cardiac disease were mild

dyslipidemia and tobacco use. His 12-lead EKG was normal. His age and family history did not contribute to a suspicion for underlying cardiac disease. He was actively running to comply with physical fitness standards and had no suspicious symptoms. The U.S. Army Aeromedical Activity (USAAMA) has a coronary artery disease (CAD) risk policy for individuals over the age of 40. Aircrew who do not meet nominal lipid profile standards are considered a CAD Level 1 failure. This mandates a GXT, or CAD Level 2 testing. USAAMA's Metabolic Syndrome policy accounts for factors such as obesity, hypertension, dyslipidemia, and elevated fasting blood sugar. The policy requires a GXT for individuals of any age who fail to meet established standards. In this case the patient would have passed the stress test triggered by either policy and been in compliance with standards for flying duties. In fact he did have a normal GXT after the BAV was identified.

Multiple sources have suggested that primary care point-of-care ultrasound (POCUS) technology is "the new stethoscope." Because primary care POCUS is increasing in availability and various medical colleges are incorporating standards and training in their undergraduate medical school curriculum, its use in cases such as this merits discussion. POCUS evaluations take additional clinical time to perform and they should not replace the routine proficient history or skilled cardiac auscultatory physical examination. POCUS evaluations should not replace more comprehensive studies conducted by sonographers and cardiologists when indicated by history, physical, and even POCUS exam findings. The role of cardiac POCUS should be complementary to auscultation in primary care aviation medicine and used to confirm the absence of serious pathology when the flight surgeon suspects an innocent etiology. POCUS could also help the flight surgeon to isolate and define an area of auscultated suspected pathology to help better guide cardiology referrals.

The Chinese University at Hong Kong studied the implementation of POCUS cardiac exam during a 2-wk anesthesia rotation taken by final-year medical students. Researchers found that 82% of the students were able to accurately obtain transthoracic echocardiography views using GE Vscan devices (GE Healthcare, Fairfield, CT).⁷ The authors concluded that this supports the feasibility of early medical education in POCUS cardiac ultrasound in spite of limited available openings in existing curriculum. Stokke et al. found that with only 4 h of training, medical students in their clinical years could significantly improve diagnostic accuracy of mitral valve and ventricular defects using hand-held ultrasound when compared with auscultation.¹⁵

Although 4 h of training was enough to effect improved diagnostic proficiency with POCUS in Stokke et al.'s study, it is likely not enough time for students and clinicians to develop practical clinical skills. Even skilled echocardiographers sometimes disagree with one another regarding the same images. However, what this study along with the aforementioned Hong Kong experiment does suggest is that with a relatively small amount of time and training primary care physicians can be trained in skills that can augment auscultatory identification and help them to stratify suspicious findings. A proposed schema

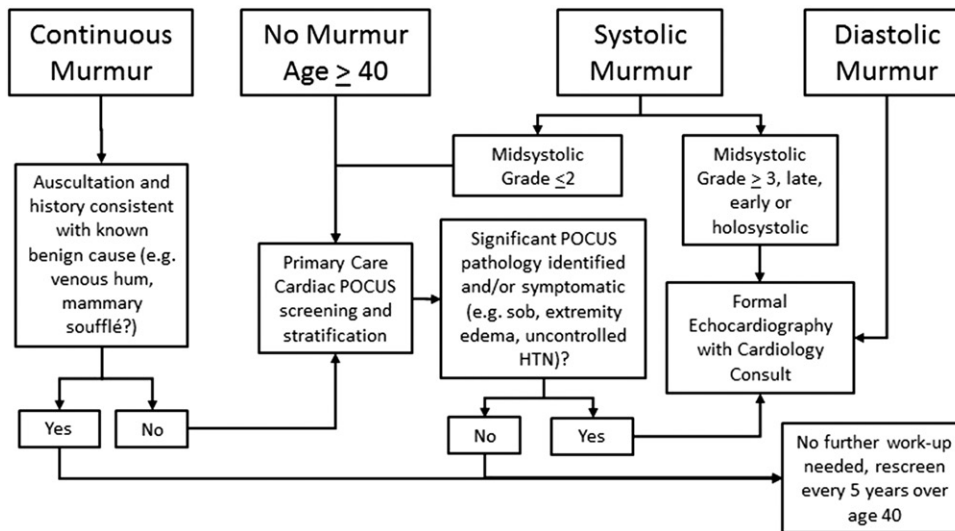


Fig. 4. Proposed schema for the implementation of efficient use of primary care cardiac POCUS for newly auscultated cardiac murmur identification and age-based risk stratification.

modified from current references to incorporate the efficient use of POCUS is presented for consideration (Fig. 4).⁴ Once established, a primary care cardiac POCUS standard could provide another layer of screening at a lower cost than traditional echocardiography when indicated by age, history, and physical exam. The optimal indications and training curricula for primary care cardiac POCUS need to be studied further.

Finally, the use of screening POCUS during flight physicals starting at age 40 might prove to be a reasonable and beneficial complement to auscultation for earlier diagnosis of both valvular and ventricular heart disease as well as abdominal aortopathy. In this patient's case the identification of BAV at age 40 would have allowed for earlier and more systematic monitoring of the patient. This would be consistent with the intent of USAAMA's CAD screening guidelines. Active duty and reserve military aviation personnel generally complete their flying careers at a younger age than civilian aviation personnel. Military aviators undergo more rigorous entry selection than professional civilian pilots and are also required to maintain some level of cardiovascular fitness as part of being in the military. Under current U.S. Federal Aviation Administration (FAA) standards, pilots exercising the privileges of Air Transport Pilots can fly to age 65 and there is no fitness standard or specific cardiac screening required with an FAA Class I medical exam other than an annual EKG over 40 with a baseline exam at 35. Given the FAA's recent interest in the implications to safety of flight for obesity and obstructive sleep apnea and those two conditions' association with cardiac events, future research should include a risk benefit analysis of implementing screening cardiac POCUS in commercially employed pilots and military aviators as they age. Specifically, it is better to know of a potential problem, monitor it, and manage it while keeping a valuable and expensive asset such as a flight medic, pilot, or military aviator operating than to wait for an adverse event to occur.

This case demonstrates the continued value of the stethoscope and the importance of skill and practice in its clinical

use nearly 200 yr after Rene Laennec invented the device. In this case given the subtle intensity of the auscultated murmur and the relatively rapid progression of disease, it was fortuitous for the patient that the lesion was found before it caused significant disability.

ACKNOWLEDGMENTS

The authors would like to thank Kelly Nottingham, MA, Office of Research and Grants, Ohio University Heritage College of Osteopathic Medicine, for her assistance in the preparation of this report.

The views expressed herein are those of the author and do not reflect the official policy of the National Guard, Department of the Army, Department of Defense, the U.S. Government, or the Ohio University Heritage College of Osteopathic Medicine.

Authors and affiliations: Todd R. Fredricks, B.S., D.O., Assistant Professor of Family Medicine, and Jeffrey S. Benseler, B.S., D.O., Associate Professor of Specialty Medicine, Ohio University Heritage College of Osteopathic Medicine, Athens, OH.

REFERENCES

- Abbott M. Coarctation of the aorta of the adult type. *Am Heart J.* 1928; 3(5):574–618.
- Attenhofer Jost CH, Turina J, Mayer K, Seifert B, Amann FW, et al. Echocardiography in the evaluation of systolic murmurs of unknown cause. *Am J Med.* 2000; 108(8):614–620.
- Barrett MJ, Lacey CS, Sekara AE, Linden EA, Gracely EJ. Mastering cardiac murmurs: the power of repetition. *Chest.* 2004; 126(2):470–475.
- Bonow RO, Carabello BA, Chatterjee K, de Leon AC, Faxon DP, et al. 2008 Focused Update Incorporated Into the ACC/AHA 2006 Guidelines for the Management of Patients With Valvular Heart Disease: A Report of the American College of Cardiology/American Heart Association Task Force on Practice Guidelines (Writing Committee to Revise the 1998 Guidelines for the Management of Patients With Valvular Heart Disease). Endorsed by the Society of Cardiovascular Anesthesiologists, Society for Cardiovascular Angiography and Interventions, and Society of Thoracic Surgeons. *J Am Coll Cardiol.* 2008; 52(13):e1–e142.
- Chizner MA. Cardiac auscultation: rediscovering the lost art. *Curr Probl Cardiol.* 2008; 33(7):326–408.
- Cripe L, Andelfinger G, Martin LJ, Shooner K, Benson DW. Bicuspid aortic valve is heritable. *J Am Coll Cardiol.* 2004; 44(1):138–143.
- Ho AM, Critchley LA, Leung JY, Kan PK, Au SS, Ng SK. Introducing final-year medical students to pocket-sized ultrasound imaging: teaching transthoracic echocardiography on a 2-week anesthesia rotation. *Teach Learn Med.* 2015; 27(3):307–313.
- Itagaki S, Chiang Y, Tang GH. Why does the bicuspid aortic valve keep eluding us? *Cardiol Rev.* 2015 Jan. 13. [pub ahead of print].
- Losenno KL, Goodman RL, Chu MW. Bicuspid aortic valve disease and ascending aortic aneurysms: gaps in knowledge. *Cardiol Res Pract.* 2012; 2012:145202.
- Mangione S, Nieman LZ. Cardiac auscultatory skills of internal medicine and family practice trainees. A comparison of diagnostic proficiency. *JAMA.* 1997; 278(9):717–722 (Erratum in: *JAMA* 1998; 279(18):1444).

11. Ostfeld RJ, Goldberg YH, Janis G, Bobra S, Polotsky H, Silbiger S. Cardiac auscultatory training among third year medical students during their medicine clerkship. *Int J Cardiol.* 2010; 144(1):147–149.
12. Roldan CA, Shively BK, Crawford MH. Value of the cardiovascular physical examination for detecting valvular heart disease in asymptomatic subjects. *Am J Cardiol.* 1996; 77(15):1327–1331.
13. Siu SC, Silversides CK. Bicuspid aortic valve disease. *J Am Coll Cardiol.* 2010; 55(25):2789–2800.
14. Spatz ES, LeFrancois D, Ostfeld RJ. Developing cardiac auscultation skills among physician trainees. *Int J Cardiol.* 2011; 152(3): 391–392.
15. Stokke TM, Ruddox V, Sarvari SI, Otterstad JE, Aune E, Edvardsen T. Brief group training of medical students in focused cardiac ultrasound may improve diagnostic accuracy of physical examination. *J Am Soc Echocardiogr.* 2014; 27(11):1238–1246.
16. Tzemos N, Therrien J, Yip J, Thanassoulis G, Tremblay S, et al. Outcomes in adults with bicuspid aortic valves. *JAMA.* 2008; 300(11):1317–1325.
17. Vukanovic-Criley JM, Criley S, Warde CM, Boker JR, Guevara-Matheus L, et al. Competency in cardiac examination skills in medical students, trainees, physicians, and faculty: a multicenter study. *Arch Intern Med.* 2006; 166(6):610–616.