

9. Owyang C. Pancreatitis. In: Goldman L, Ausiello D, eds. Cecil textbook of medicine, 22nd ed. Philadelphia: Saunders; 2004:880-1.
10. Prasad GA, Alexander JA, Schleck CD, Zinsmeister AR, Smyrk TC, et al. Epidemiology of eosinophilic esophagitis over three decades in Olmsted County, Minnesota. *Clin Gastroenterol Hepatol* 2009; 7:1055-61.
11. Schwartz LB. Systemic anaphylaxis. In: Goldman L, Ausiello D, eds. Cecil textbook of medicine, 22nd ed. Philadelphia: Saunders; 2004:1616.
12. Semrad CE, Powell DW. Approach to the patient with diarrhea and malabsorption. In: Goldman L, Ausiello D, eds. Cecil textbook of medicine, 22nd ed. Philadelphia: Saunders; 2004:844.
13. U.S. Army. 4-4. Abdomen and gastrointestinal system; 4-18. Lung and chest wall. In: Standards of medical fitness. Washington, DC: Department of the Army; 2011:41,45. Army Regulation 40-501. Retrieved 19 March 2014 from http://armypubs.army.mil/epubs/pdf/r40_501.pdf.

This article was prepared by Jeffrey Lee Moore, D.O., Cody R. Jackson, M.D., Jeffrey C. Ellis, PA-C, and Corrienne Norrid, NC.

You are the flight surgeon in an overseas clinic on your way out to lunch when the clinic's physician assistant (PA) asks you about a patient. A 36-yr-old male patient presents with left-sided upper back pain just below the angle of the scapula that radiates to the front at the costal margin. The pain woke him up from sleep the night prior, but he was able to fall back asleep. Vital signs show a body mass index of 32, blood pressure of 138/92, and pain 8/10, and are otherwise normal. The electrocardiogram and review of systems are unremarkable. His physical exam is normal except he is very tender to palpation in the left upper quadrant with a palpable abnormality. The patient is very vocal and guards on exam. Radiology and laboratory are closed for lunch.

As the supervisory physician, you examine the patient, based on the concern expressed by the PA. In the 15 min it took to discuss the case, the abdomen is now nontender, which is a surprise to both the patient and the PA. In the left upper quadrant, at the border of the rectus muscle and ribs, you feel a small, round 1-cm lump. It is rubbery, mobile, and nontender, and determined to be a noncontributory lipoma. The patient was given a gastrointestinal cocktail and discharged with instructions to go to the emergency room for worsening symptoms or to follow up the next day.

Later that evening, the patient reported to the emergency room with increased abdominal pain, nausea, vomiting, and radiating flank pain to the groin. He had no fever, dysuria, hematemesis, or gross hematuria. A computed tomography (CT) showed a large, heterogeneous, left suprarenal, nonenhancing, well-encapsulated mass with mixed fatty and soft tissue attenuation without calcification measuring 17 cm × 14 cm × 12 cm (**Fig. 1**). No left adrenal gland was seen. This mass did not appear to invade the adjacent structures. No adenopathy was identified. There was mass effect on the left kidney, spleen, pancreas, and bowel in the left upper quadrant. The scan was otherwise unremarkable.

1. Based on the radiologic finding, what would your treatment plan entail?

- A. Pain control.
- B. Discharge home.
- C. Urology referral.
- D. Medical evacuation.
- E. All of the above.

ANSWER/DISCUSSION

1. E. Taking into consideration that you are in a small overseas hospital with only orthopedic, obstetric, and general surgeons, all of the above answers are correct. Pain control and discharge home with close primary care manager follow-up are essential for monitoring the patient's status while awaiting medical evacuation. If oral pain control fails or his presentation worsens, hospital admission can always be considered. Getting the patient to a urologic specialist is imperative to the patient's care. Contact was made with the regional medical center and it was advised that the patient be sent to a higher level of care near his family. Tumors of this size in a young individual have a poor prognosis.⁷ Medical evacuation is the best way to get the patient home for workup, removal, and pathological diagnosis.

Before you can narrow down the diagnoses, it is helpful to determine the severity of the lesion from the CT imaging. When dealing with cystic renal masses, the Bosniak Classification is helpful in diagnosing and managing these lesions through CT evaluation (6). CT imaging allows us to see certain morphologic features along with enhancement characteristics that guide the need for further evaluation and determine malignant risks that likely require further follow-up. The Bosniak Classification is categorized into five different groups:

- Category I – A benign simple renal cyst
 - Features: Thin walled, no septa, no calcifications, and no solid components
 - Attenuation: Low, like that of water
 - Enhancement: None
 - Workup: None
 - Malignancy: ~0%
- Category II – Benign cystic lesions that are < 3 cm in diameter
 - Features: Thin walled, few thin septa, thin calcification, well marginated
 - Attenuation: High (due to proteinaceous or hemorrhagic fluid)
 - Enhancement: None
 - Workup: None
 - Malignancy: ~0%

DOI: 10.3357/AMHP.4026.2015

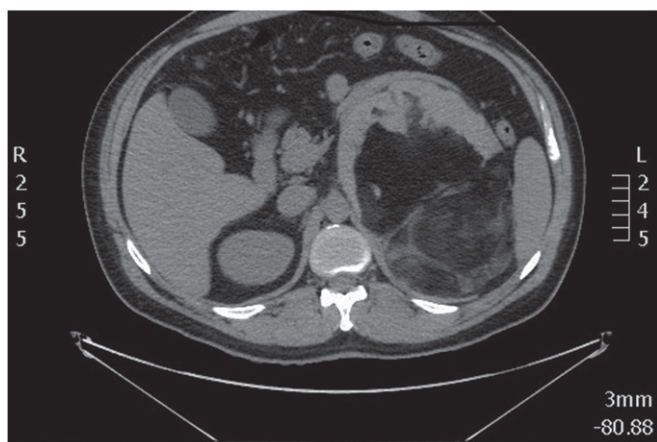


Fig. 1. CT slice showing the mass.

- Category IIF (F for follow-up) – Minimally complex cystic lesions that are > 3 cm in diameter and require follow-up to ensure benignity
 Features: Minimally smooth thickened wall, increased number of minimally thickened or enhancing septa, thick calcification but without measurable contrast enhancement, well marginated.
 Attenuation: High
 Enhancement: None; however, lesions may have perceived enhancement of the septa or wall, which is due to subjective (and not measurable) enhancement when the unenhanced and contrast-enhanced images are compared.
 Workup: Needs ultrasound or CT follow-up.
 Malignancy: ~25%¹⁵
- Category III – Indeterminate cystic lesions
 Features: Thickened irregular or smooth wall, thickened or measurably enhanced septa, measurable contrast enhancement.
 Attenuation: High
 Enhancement: Present
 Workup: Surgical resection
 Malignancy: ~54% (cystic renal cell carcinoma and multiloculated cystic renal cell carcinoma). The remaining lesions are benign and include hemorrhagic cysts, chronic infected cysts, and multiloculated cystic nephroma.¹⁵
- Category IV – Malignant cystic lesions
 Features: Clearly malignant cystic masses that have all the characteristics of Category III cysts, plus they contain enhancing soft-tissue components that are adjacent to and independent of the wall or septum.
 Attenuation: High
 Enhancement: Present
 Workup: Surgical resection
 Malignancy: ~100%

The presence of true contrast enhancement of the lesion (a minimum increased attenuation of 10 to 15 Hounsfield units) is the most important characteristic separating categories III and IV.⁸ From the CT interpretation given to you by the radiologist in his report, your

patient would be categorized as having a Bosniak Category IIF lesion.

2. Based on the CT findings, what would your most likely diagnosis be?

- Renal cell carcinoma.
- Oncocytoma.
- Teratoma.
- Myelolipoma.
- Liposarcoma.

ANSWER/DISCUSSION

2. D. Renal cell carcinomas (RCCs) (Bosniak Category IV lesion), which originate within the renal cortex, are responsible for 80–90% of all primary malignant renal neoplasms. Clear cell carcinomas, which account for approximately 80% of RCC tumors and typically have a deletion of chromosome 3p (associated with von Hippel-Lindau disease), arise from the proximal tubule. Macroscopically, they vary in appearance, ranging from solid and relatively homogeneous to markedly heterogeneous.¹¹ On noncontrast CT, lesions appear with soft tissue attenuation. Larger lesions often have areas of necrosis and about 30% of them have some calcification. Due to necrotic areas, lesions often show variable enhancement with contrast.¹⁴ A diagnosis of RCC for the patient is not likely given the fact that the lesion was extrarenal and non-enhancing; was absent of calcification, necrosis, septae, or hemorrhage; and had a well-circumscribed, noninvasive, smooth-walled border.

Oncocytomas (Bosniak Category IIF or higher lesion) account for about 3–7% of all renal tumors and appear to originate from the intercalated cells of the collecting ducts. On CT imaging, it is difficult to distinguish an oncocytoma from RCC, but typically they are seen as a homogeneous, well-circumscribed, encapsulated solid mass containing a central scar.¹² They are rarely invasive or associated with metastases even at a large size.³ During noncontrast CT, lesions greater than 3 cm usually have a heterogeneous attenuation, there is perinephric fat-stranding, and calcification can be present. Contrast CT demonstrates heterogeneity and the central, nonenhancing scar may be seen one-third of the time.¹⁴ As the demographics and imaging studies are similar to RCC, surgical resection is recommended. An oncocytoma diagnosis is unlikely given the fact that the lesion was extrarenal, nonenhancing, heterogeneous, and absent of calcification or central scarring.

Teratomas (Bosniak Category III lesion or higher) are the most common type of germ cell neoplasm and are mostly benign. By definition, they contain elements from all three embryological layers. The component tissues in a teratoma range from immature poorly differentiated lesions (often malignant) to mature, well-differentiated lesions (usually benign). The majority of teratomas are seen in the ovary, testis, mediastinum, and around the central nervous system. CT has a high sensitivity in the diagnosis of cystic teratomas.¹ Malignant transformation should be suspected whenever size exceeds 10 cm, soft tissue plugs are present, and there is a cauliflower appearance with irregular borders seen.⁵ A teratoma is also not likely

the diagnosis because the lesion did not demonstrate any calcifications, a dermoid plug, or tuft of hair.

Usually occurring in the sixth and seventh decade of life, liposarcomas (Bosniak Category IV) are the second most common type of soft-tissue sarcoma, accounting for 10–35% of all soft-tissue sarcomas. Liposarcomas generally fall into three CT attenuation patterns depending on the amount and distribution of fat within the tumor: solid, mixed, and pseudocystic.² CT findings that favor a diagnosis of liposarcoma include heterogeneous attenuation, large quantity (> 75%) of adipose tissue within the lesion, poor definition of adjacent structures, lesions > 10 cm, thick/nodular septa/wall, and evidence of infiltration/invasion of mediastinal structures.⁹ A liposarcoma is less likely, although the size of the lesion, the large quantity of soft tissue within the lesion, and the mixed attenuation pattern could be suggestive of this diagnosis.

Generally, adrenal myelolipomas (Bosniak Category IIF or higher lesion) appear as an adrenal mass with fat-containing components. They have a very specific appearance, as they most commonly originate from the adrenal gland, and they are usually well circumscribed. The amount of fatty component is highly variable, ranging from 50–90%.¹⁶ Small punctate calcifications may be seen in ~25% of cases.⁵ Hemorrhage is more commonly seen in larger lesions (> 10 cm).¹³ A myelolipoma is the most likely diagnosis given the location of the lesion with marked absence of the adrenal gland, the size of the lesion, the mixed attenuation pattern, and the well-circumscribed capsule with lack of invasion/infiltration.

The patient was routinely medically evacuated back to the States for surgery. The pathology report confirmed that the cabbage-sized mass was a myelolipoma. After convalescence he returned overseas asymptomatic, normotensive, and 40 lb lighter. With only one kidney, the member's duty status is limited and continued military service is questionable.

From an aeromedical standpoint, splenectomy and nephrectomy are waiverable on a case-by-case basis in the U.S. military services. Removal of the spleen after trauma does not require a waiver. Renal tumors that are benign may be eligible for waiver once returned to full duty. However, tumors that are malignant require a 2-yr waiting period prior to a waiver. The Federal Aviation Administration may return the patient to flying status if the remaining kidney is functioning normally. The Federal Aviation Administration does not comment specifically on the absence of the spleen in the Guide for Aviation Medical Examiners.^{4,10,17,18}

Moore JL, Jackson CR, Ellis JC, Norrid C. You're the flight surgeon: myelolipoma. *Aerosp Med Hum Perform.* 2015; 86(4):421–423.

REFERENCES

- Buy JN, Ghossain MA, Moss AA, Bazot M, Doucet M, et al. Cystic teratoma of the ovary: CT detection. *Radiology* 1989; 171:697–701.
- Craig WD, Fanburg-Smith JC, Henry LR, Guerrero R, Barton JH. Fat-containing lesions of the retroperitoneum: radiologic-pathologic correlation. *Radiographics* 2009; 29:261–90.
- Dechet CB, Bostwick DG, Blute ML, Bryant SC, Zincke H. Renal oncocytoma: multifocality, bilateralism, metachronous tumor development and coexistent renal cell carcinoma. *J Urol* 1999; 162:40–2.
- Federal Aviation Administration. Guide for aviation medical examiners. Washington, DC: Federal Aviation Administration; 2014. Retrieved 15 March 2014 from http://www.faa.gov/about/office_org/headquarters_offices/avs/offices/aam/ame/guide/media/guide.pdf.
- Friedman AC, Pyatt RS, Hartman DS, Downey EF Jr, Olson WB. CT of benign cystic teratomas. *AJR Am J Roentgenol* 1982; 138:659–65.
- Israel GM, Bosniak MA. An update of the Bosniak renal cyst classification system. *Urology* 2005; 66:484–8.
- Kransdorf MJ, Bancroft LW, Peterson JJ, Murphey MD, Foster WC, Temple HT. Imaging of fatty tumors: distinction of lipoma and well-differentiated liposarcoma. *Radiology* 2002; 224:99–104.
- Luke LC, Cusack S, Smith H, Robertson CE, Little K. Non-traumatic chest pain in young adults: a medical audit. *Arch Emerg Med* 1990; 7:183–8.
- Murphey MD, Arcara LK, Fanburg-Smith J. From the archives of the AFIP: imaging of musculoskeletal liposarcoma with radiologic-pathologic correlation. *Radiographics* 2005; 25:1371–95.
- Naval Aerospace Medical Institute. Aeromedical reference and waiver guide. Pensacola, FL: Naval Aerospace Medical Institute; 2014. Retrieved 15 March 2014 from <http://www.med.navy.mil/sites/nmotc/nami/arwg/Pages/default.aspx>.
- Ng CS, Wood CG, Silverman PM, Tannir NM, Tamboli P, Sandler CM. Renal cell carcinoma: diagnosis, staging, and surveillance. *AJR Am J Roentgenol* 2008; 191:1220–32.
- Prasad SR, Surabhi VR, Menias CO, Raut AA, Chintapalli KN. Benign renal neoplasms in adults: cross-sectional imaging findings. *AJR Am J Roentgenol* 2008; 190:158–64.
- Routhier JR, Woodfield CA, Mayo-Smith WW. AJR teaching file: fat-containing retroperitoneal mass presenting with acute flank pain. *AJR Am J Roentgenol* 2009; 192:S122–4.
- Sheth S, Scatarige JC, Horton KM, Corl FM, Fishman EK. Current concepts in the diagnosis and management of renal cell carcinoma: role of multidetector CT and three-dimensional CT. *Radiographics* 2001; 21:S237–54.
- Smith AD, Remer EM, Cox KL, Lieber ML, Allen BC, et al. Bosniak category IIF and III cystic renal lesions: outcomes and associations. *Radiology* 2012; 262:152–60.
- Thompson RH, Kurta JM, Kaag M, Tickoo SK, Kundu S, et al. Tumor size is associated with malignant potential in renal cell carcinoma cases. *J Urol* 2009; 181:2033–6.
- U.S. Air Force School of Aerospace Medicine. Air Force waiver guide. Wright-Patterson AFB, OH: U.S. Air Force School of Aerospace Medicine; 2013. Retrieved 15 March 2014 from <http://www.wpafb.af.mil/shared/media/document/AFD-130118-045.pdf>.
- U.S. Army Aeromedical Activity. Aeromedical policy letters. Fort Rucker, AL: U.S. Army Aeromedical Activity; 2014. Retrieved 11 July 2014 from http://www.rucker.amedd.army.mil/assets/documents/pdf/Army_APLs_28may2014.pdf.